

Monkeypox Virus Infection in 2 Female Travelers Returning to Vietnam from Dubai, United Arab Emirates, 2022

Nguyen Thanh Dung, Le Manh Hung, Huynh Thi Thuy Hoa, Le Hong Nga, Nguyen Thi Thu Hong, Tang Chi Thuong, Nghiem My Ngoc, Nguyen Thi Han Ny, Vo Truong Quy, Vu Thi Kim Thoa, Nguyen Thi Thanh, Phan Vinh Tho, Le Mau Toan, Vo Minh Quang, Dinh Nguyen Huy Man, Nguyen Tan Phat, Tran Thi Lan Phuong, Tran Thi Thanh Tam, Pham Thi Ngoc Thoa, Nguyen Hong Tam, Truong Thi Thanh Lan, Tran Tan Thanh, Sebastian Maurer-Stroh, Le Thuy Thuy Khanh, Lam Minh Yen, Nguyen Huu Hung, Guy Thwaites, Nguyen Le Nhu Tung, Louise Thwaites, Nguyen Van Vinh Chau, Nguyen To Anh, Le Van Tan

Mpox was diagnosed in 2 women returning to Vietnam from the United Arab Emirates. The monkeypox viruses belonged to an emerging sublineage, A.2.1, distinct from B.1, which is responsible for the ongoing multicountry outbreak. Women could contribute to mpox transmission, and enhanced genomic surveillance is needed to clarify pathogen evolution.

By January 12, 2023, more than 84,500 mpox cases and 80 deaths had been reported from 110 countries because of an ongoing multicountry outbreak (1). Cases from Europe and Americas accounted for >98% of reported cases, and only 35 cases had been reported from Southeast Asia (1). The outbreak has been characterized by involvement of networks of men who have sex with

men; women have accounted for only 3.4% of 74,673 reported cases for which gender data were available (1). We report virologic, epidemiologic, and clinical features of mpox occurring in 2 women returning to Vietnam from travel to Dubai, United Arab Emirates.

The Study

The case-patients were treated at the Hospital for Tropical Diseases (HTD) in Ho Chi Minh City, Vietnam. HTD is a tertiary referral infectious diseases hospital and the designated hospital for receiving and treating mpox patients in Ho Chi Minh City, which has a population of ≈10 million. The study was approved by the HTD Institutional Review Board (approval no. 1066/BVBND-HDDD) and Oxford Tropical Research Ethics Committee (approval no. 1023-13). The patients provided written informed consent for the study.

Patient 1 was a 35-year-old woman who was referred to HTD in September 2022. At admission, she had maculopapular lesions on various parts of her body (Figure 1, panels A–D), including the genital area (not shown). The patient had been in Dubai during July–September 2022 and had sexual contact with 2 male partners during her stay. The most recent contact was in mid-September; 5 days after the contact, she had fever, headache, chills, cough, sore throat, muscle pain, and tiredness, accompanied by a maculopapular rash in the genital area. Her symptoms resolved after 4 days except for the rash, and she returned to HCMC. Upon returning, additional

Author affiliations: Hospital for Tropical Diseases, Ho Chi Minh City, Vietnam (N.T. Dung, L.M. Hung, H.T.T. Hoa, N.M. Ngoc, V.T. Quy, V.T.K. Thoa, N.T. Thanh, P.V. Tho, L.M. Toan, V.M. Quang, D.N.H. Man, N.T. Phat, T.T.L. Phuong, T.T.T. Tam, P.T.N. Thoa, N.L.N. Tung); Center for Disease Control, Ho Chi Minh City (L.H. Nga, N.H. Tam, T.T.T. Lan); Oxford University Clinical Research Unit, Ho Chi Minh City (N.T.T. Hong, N.T.H. Ny, T.T. Thanh, L.T.T. Khanh, L.M. Yen, G. Thwaites, L. Thwaites, N.T. Anh, L.V. Tan); Department of Health, Ho Chi Minh City (T.C. Thuong, N.H. Hung, N.V.V. Chau); Agency for Science, Technology and Research, Singapore (S. Maurer-Stroh); University of Oxford, Oxford, England, UK (G. Thwaites, L. Thwaites, L.V. Tan)

DOI: <https://doi.org/10.3201/eid2904.221835>

lesions developed in her mouth and on her back and upper and lower limbs. No information on the clinical status or sexual orientation of her partners was available. Her admission lesion swab tested positive for monkeypox virus (MPXV) by LightMix Modular Monkeypox Virus Kit (TIB Molbiol, <https://www.tib-molbiol.de>) with a cycle threshold (Ct) value of 18.05 (Appendix Table 1, <https://wwwnc.cdc.gov.EID/article/29/4/22-1835-App1.pdf>) and for varicella zoster virus (VZV) by VZV Real-TM (Sacace Biotechnologies, <https://sacace.com>) with a Ct of 30.5.

Patient 2 was a 38-year-old woman who was a friend of patient 1. She reported that she was in Dubai during late September through mid-October 2022 and had a sexual encounter with a male partner at in early October. She noted that the partner had a small rash on his penis and mild fever on the day of the encounter. No information about the partner's other sexual contacts is available. Nine days after the contact, she had fever, tiredness, and vomiting. Although her symptoms resolved after 4 days, a maculopapular rash started to develop on various parts of her body, including her face, a finger of the left hand, the arch of her right foot, and her abdomen (Figure 1, panels E–H). After consulting patient 1, patient 2 decided to fly back to Vietnam for treatment. Before departure she contacted Ho Chi Minh City Center for Disease Control for guidance on the isolation procedure at arrival. Patient 2 was transferred to HTD on arrival. She tested positive for MPXV by PCR at admission via LightMix Modular Monkeypox Virus Kit with a Ct value of 19.40.

At admission to HTD, both patients were afebrile. Except for an elevated alanine aminotransferase in patient 2, all blood test results were unremarkable

(Appendix Table 2). All vital signs during hospitalization were measured by using wearable devices (Appendix Figure), as part of an observational study to enable remote patient monitoring (2), and measurements were within reference limits (data not shown). Test results for HIV and syphilis were negative. Because of the VZV coinfection, supporting a recent report (3), patient 1 was given oral acyclovir (800 mg 5×/d for 5 d). No other specific treatments were given. The patients were isolated, according to local health regulations, and their conditions remained stable without complications. After all lesions were completely healed, they were discharged.

To characterize the virus, we used metagenomics to obtain whole-genome sequences from the admission swab sample from patient 2 and a lesion swab sample with Ct value of 18.19 collected from patient 1 during follow-up (4,5) (Appendix, Appendix Table 1). We obtained 2 nearly complete MPXV genomes with coverage of 97.7% from patient 1 and 95% from patient 2. We determined viral lineage by using Next-Clade (6). Phylogenetic analysis suggested the sequences belonged to clade IIb, sublineage A.2.1 (Figure 2). Both sequences carried defined mutations of sublineage A.2.1, including C25072T, A140492C, and C179537T (7). In addition, we found a novel nonsynonymous substitution from threonine to isoleucine in amino 717 (T717I) of the polymerase protein in the sequence from patient 1. This mutation was not detected in any previously reported MPXV genomes. The estimated time to the most recent common ancestor of lineage A.2, including sublineage A.2.1, was May 27, 2019 (range August 3, 2018–January 23, 2020).

Additional samples were collected from patient 1 for PCR testing during follow up. Of those, 1 rectal (Ct

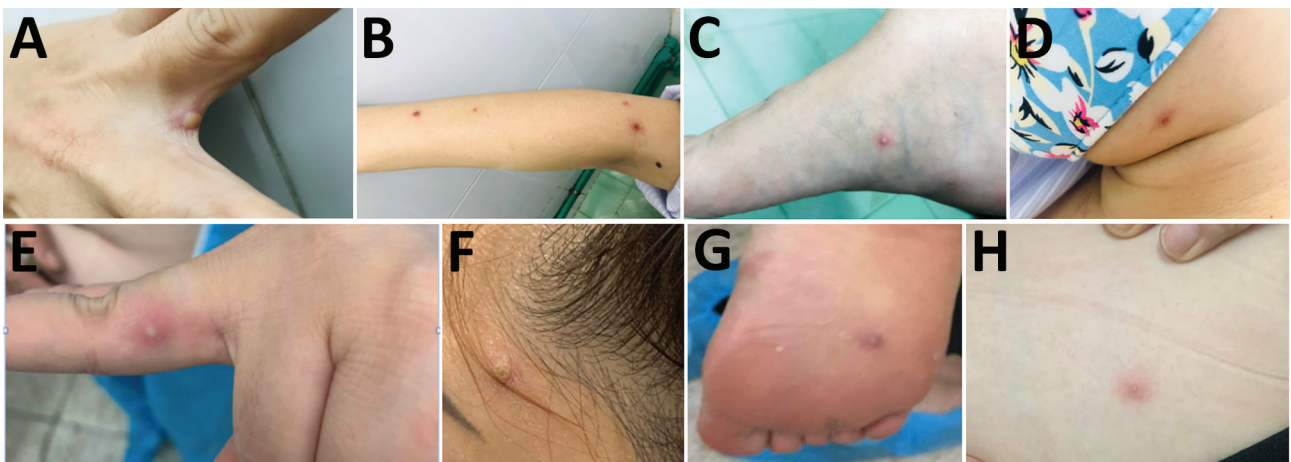


Figure 1. Monkeypox virus lesions from 2 female travelers returning to Vietnam from Dubai, United Arab Emirates, 2022. A–D) patient 1; E–H) patient 2. Images show lesions sporadically distributed on different body parts, including on patient 1 between 2 fingers (A), right arm (B), right foot (C), and face (D); and for patient 2, on a finger (E), the face (F), the arch of the right foot (G), and abdomen (H).

(<https://www.gisaid.org>) originated in the United Kingdom, the United States, and Nigeria (Figure 1). Because MPXV evolves slowly, the genetic difference between the 2 sequences in this study coupled with the long branches of the A.2.1 cluster on the phylogenetic tree point to the possibility of silent transmission. Alternatively, the current sampling approach might have failed to comprehensively capture the genetic diversity of circulating MPXV strains worldwide. Collectively, these data suggest that lineage A.2, including sublineage A.2.1, likely represents an emerging MPXV lineage, supported by the results of time-scale phylogenetic analysis. Thus, multiple MPXV lineages likely are circulating and causing the ongoing multicountry outbreak.

Conclusions

We report 2 MPXV infections in women returning to Vietnam from Dubai, adding to the few reports of mpox in women (10,11). The viral strain belonged to sublineage A.2.1 and was phylogenetically distinct from sublineage B.1 circulating and causing the ongoing multicountry outbreak in Europe and Americas (9,12). Both patients had sexual contacts with male partners in Dubai, 5 and 9 days before symptoms developed. Our findings suggest that contribution of women in MPXV transmission networks might be greater than previously appreciated. Enhanced genomic surveillance is needed to clarify the epidemiology and evolution of MPXV.

Acknowledgments

We thank the patients for participating in our clinical study and our colleagues at the Hospital for Tropical Diseases for providing clinical care for the patients. We also thank Le Kim Thanh and Lam Anh Nguyet for logistic support and Tze Minn Mak for support with data interpretation. We thank all data contributors and their laboratories for obtaining the specimens for this study, and we thank the laboratories that submitted and shared their generated genetic sequence and metadata via GISAID, on which this research is based.

This study was funded by Wellcome of Great Britain (grant nos. 106680/B/14/Z, 222574/Z/21/Z, and 225437/Z/22/Z).

About the Author

Dr. Dung is director of the Hospital for Tropical Diseases in Ho Chi Minh City, Vietnam. His research interests include hepatitis viruses and emerging infections.

References

- World Health Organization. 2022 Mpox (Monkeypox) outbreak: global trends [cited 2023 Jan 12]. https://worldhealthorg.shinyapps.io/mpx_global
- Chau NVV, Hai HB, Greeff H, Phan Nguyen Quoc K, Trieu HT, Khoa LDV, et al. Wearable remote monitoring for patients with COVID-19 in low-resource settings: case study. *BMJ Innov.* 2021;7(Suppl 1):s12-5. <https://doi.org/10.1136/bmjinnov-2021-000706>
- Hughes CM, Liu L, Davidson WB, Radford KW, Wilkins K, Monroe B, et al. A Tale of two viruses: coinfections of monkeypox and varicella zoster virus in the Democratic Republic of Congo. *Am J Trop Med Hyg.* 2020;104:604-11. <https://doi.org/10.4269/ajtmh.20-0589>
- Anh NT, Hong NTT, Nhu LNT, Thanh TT, Lau CY, Limmathurotsakul D, et al. Viruses in Vietnamese patients presenting with community-acquired sepsis of unknown cause. *J Clin Microbiol.* 2019;57:e00386-19. <https://doi.org/10.1128/JCM.00386-19>
- Nguyen AT, Tran TT, Hoang VM, Nghiem NM, Le NN, Le TT, et al. Development and evaluation of a non-ribosomal random PCR and next-generation sequencing based assay for detection and sequencing of hand, foot and mouth disease pathogens. *Viol J.* 2016;13:125. <https://doi.org/10.1186/s12985-016-0580-9>
- Aksamentov I, Roemer C, Hodcroft E, Neher R. Nextclade: clade assignment, mutation calling and quality control for viral genomes. *J Open Source Softw.* 2021;6:3773. <https://doi.org/10.21105/joss.03773>
- Shete AM, Yadav PD, Kumar A, Patil S, Patil DY, Joshi Y, et al. Genome characterization of monkeypox cases detected in India: identification of three sub clusters among A.2 lineage. *J Infect.* 2023;86:66-117. <https://doi.org/10.1016/j.jinf.2022.09.024>
- Ulaeto DO, Dunning J, Carroll MW. Evolutionary implications of human transmission of monkeypox: the importance of sequencing multiple lesions. *Lancet Microbe.* 2022;3:e639-40. [https://doi.org/10.1016/S2666-5247\(22\)00194-X](https://doi.org/10.1016/S2666-5247(22)00194-X)
- Isidro J, Borges V, Pinto M, Sobral D, Santos JD, Nunes A, et al. Phylogenomic characterization and signs of microevolution in the 2022 multi-country outbreak of monkeypox virus. *Nat Med.* 2022;28:1569-72. <https://doi.org/10.1038/s41591-022-01907-y>
- Zayat N, Huang S, Wafai J, Philadelphia M. Monkeypox virus infection in 22-year-old woman after sexual intercourse, New York, USA. *Emerg Infect Dis.* 2023;29:222-3. <https://doi.org/10.3201/eid2901.221662>
- Vallée A, Chatelain A, Carbonnel M, Racowsky C, Fourn E, Zucman D, et al. Monkeypox virus infection in 18-year-old woman after sexual intercourse, France, September 2022. *Emerg Infect Dis.* 2023;29:219-22. <https://doi.org/10.3201/eid2901.221643>
- Luna N, Ramírez AL, Muñoz M, Ballesteros N, Patiño LH, Castañeda SA, et al. Phylogenomic analysis of the monkeypox virus (MPXV) 2022 outbreak: emergence of a novel viral lineage? *Travel Med Infect Dis.* 2022;49:102402. <https://doi.org/10.1016/j.tmaid.2022.102402>

Address for correspondence: Le Van Tan, Oxford University Clinical Research Unit, 764 Vo Van Kiet, ward 1, district 5, Ho Chi Minh 7000, Vietnam; email: tanlv@oucru.org

Monkeypox Virus Infection in 2 Female Travelers Returning to Vietnam from Dubai, United Arab Emirates, 2022

Appendix

Material and Methods

Metagenomic Methods and Sequence Assembly

Metagenomics was carried out as previously described (*1*). In brief, to increase the chance of success obtaining the complete genome of the virus, before nucleic acid isolation, the PCR-positive lesion swab was subjected to a pretreatment step incorporating DNase and RNase to digest unwanted background. The pretreatment reaction included 100 μ L of the lesion swab in viral transport medium, 20 U of turbo DNase and 2U RNase I (Ambion-Life Technology, ThermoFisher, <https://www.thermofisher.com>), and was incubated at 37°C for 30 min. The treated swab was then subjected to a viral DNA isolation step using DNeasy Blood & Tissue Kit (QIAGEN, <https://www.qiagen.com>), and finally separately recovered in 50 μ L of the elution buffer provided with the extraction kit.

Then, 10 μ L of the extracted DNA was converted to double stranded DNA by using a set of 96 non-ribosomal random primers (FR26RV-Endoh primers) (*1*), SuperScript III enzyme (Invitrogen, ThermoFisher Scientific, <https://www.thermofisher.com>), RNaseOUT (Invitrogen), exo-Klenow fragment (Ambion), and RNase H (Ambion). Subsequently, the synthesized dsDNA was randomly amplified using the FR20RV primer (5'-GCCGGAGCTCTGCAGATATC-3'). The obtained random PCR product was then subjected to library preparation steps by using COVIDSEQ Assay (Illumina, <https://www.illumina.com>), according to manufacturer's instructions. Prior to sequencing, the quantity and size of the prepared library was measured by using Qubit dsDNA HS kit (Invitrogen) and Agilent High Sensitivity D1000 kit (Agilent Technologies, <https://www.agilent.com>). 12 pM of the prepared library was sequenced by using MiSeq Reagent kit V3 (150 cycles) or MiSeq Nano reagent kit V2 (300 cycles) (Illumina) in a

MiSeq platform (Illumina). The sample was multiplexed and differentiated by double indexes using Nextera XT Index Kit (Illumina).

The raw sequence reads generated by Illumina MiSeq were assembled using a reference-based mapping strategy available in Geneious Prime 2022.2.2 (<https://www.geneious.com>), followed by manual editing of the obtained consensus. A monkeypox virus sequence (GISAID ID: EPI_ISL_13094227) was used as a reference.

In addition, to assess the sensitivity of the metagenomics assay in recovering the complete virus genome, a serial dilution series of the original swabs (10× and 100×) of patient 1 was prepared and sequenced using the procedure described above. The consensus sequences generated in this study were submitted to NCBI (GenBank)/GISAID and assigned accession numbers.

Phylogenetic Analysis

Pairwise alignment was performed using the tool available on Nextclade (2). Maximum likelihood phylogenetic tree was reconstructed using IQ Tree version 1.4.3 (3) applying Hasegawa Kishino Yano (HKY) nucleotide substitution model with invariant, and support for individual nodes was assessed by using a bootstrap procedure (1,000 replicates).

Time-Scale Phylogenetic Analysis

The analysis was carried on lineage A.2 sequences. The dataset consisted of 19 whole-genome sequences with available data about sampling dates. The temporal signal was assessed by using TempEst 1.5 (<http://tree.bio.ed.ac.uk/software/tempest>). Bayesian phylogenetic inference was carried in BEAST version 1.10.4 (<http://beast.community>) using HKY+Γ substitution model (as suggested by IQ Tree) under a strict clock model and constant size coalescent tree prior. A Bayesian Markov chain Monte Carlo framework (available in BEAST) was used with 50 million steps and sampling every 5,000 steps. We assessed convergence with a burn-in threshold of 10% using Tracer version 1.5 (<http://tree.bio.ed.ac.uk/software/tracer>). Maximum-clade credibility (MCC) trees were then summarized with TreeAnnotator (available in the BEAST package) and visualized in Figtree version 1.4.2 (<http://tree.bio.ed.ac.uk/software/figtree>).

References

1. Nguyen AT, Tran TT, Hoang VM, Nghiem NM, Le NN, Le TT, et al. Development and evaluation of a non-ribosomal random PCR and next-generation sequencing based assay for detection and sequencing of hand, foot and mouth disease pathogens. *Virology*. 2016;13:125. [PubMed https://doi.org/10.1186/s12985-016-0580-9](https://doi.org/10.1186/s12985-016-0580-9)
2. Aksamentov I, Roemer C, Hodcroft E, Neher R. Nextclade: clade assignment, mutation calling and quality control for viral genomes. *J Open Source Softw*. 2021;6:3773. <https://doi.org/10.21105/joss.03773>
3. Nguyen LT, Schmidt HA, von Haeseler A, Minh BQ. IQ-TREE: a fast and effective stochastic algorithm for estimating maximum-likelihood phylogenies. *Mol Biol Evol*. 2015;32:268–74. [PubMed https://doi.org/10.1093/molbev/msu300](https://doi.org/10.1093/molbev/msu300)

Appendix Table 1. PCR results for monkeypox virus infection in 2 female travelers returning to Vietnam from Dubai, United Arab Emirates, 2022*

Patient no.	Sample type	Sampling time point	Ct value
1	Lesion swab 1	At admission	18.05
1	Lesion swab 2	4 days after admission	18.19
1	Rectal swab	4 days after admission	33.30
1	Throat swab	4 days after admission	Negative
1	Vesicle swab in the mouth	5 days after admission	33.27
2	Lesion swab 1	At admission	19.4

*Ct, cycle threshold.

Appendix Table 2. Vital signs and blood tests of 2 female travelers with monkeypox virus infection after in returning to Vietnam from Dubai, United Arab Emirates, 2022*

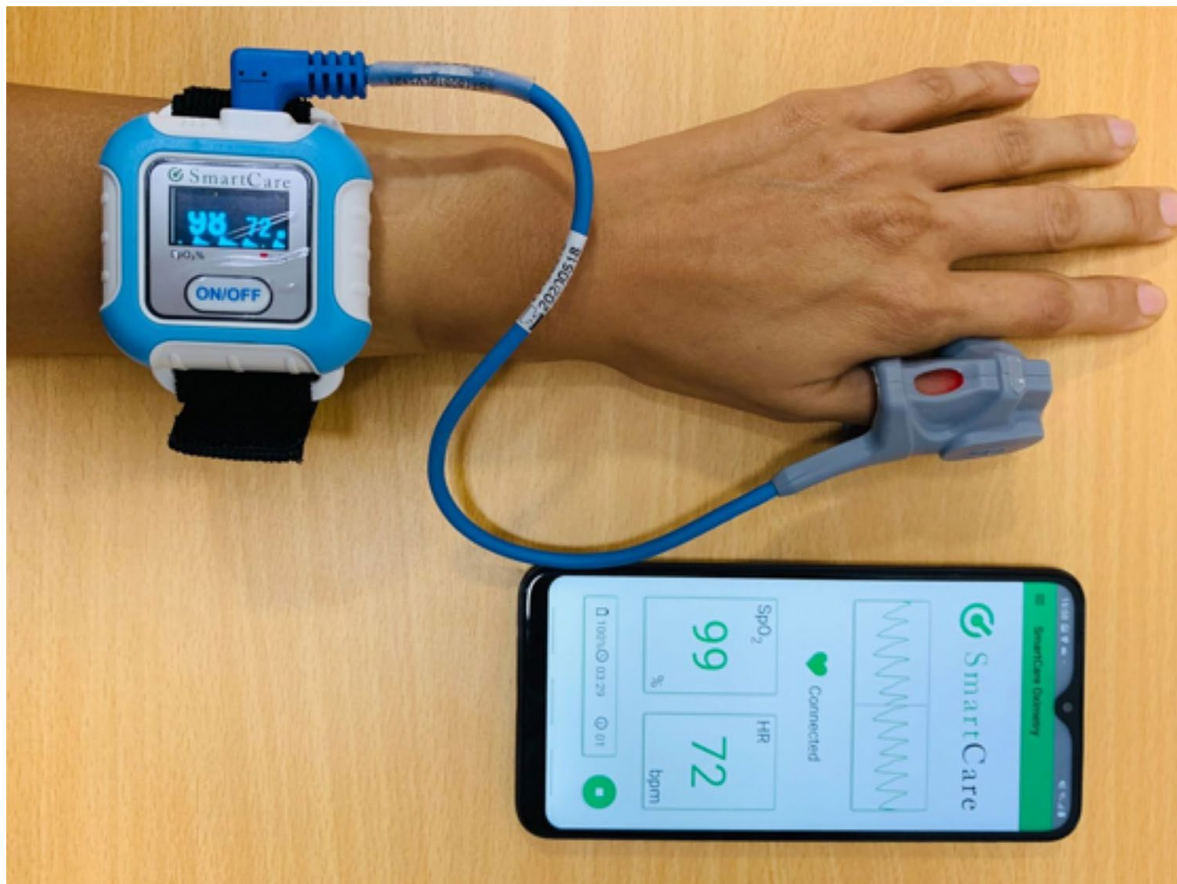Variables	Patient 1	Patient 2
Temperature	37°C	37°C
Heart rate, bpm	106	88
Respiratory rate, rpm	20	20
Blood pressure, mmHg	140/80	100/70
Leukocyte count, cells ×10 ⁹ /L	9.37	11.96
Neutrophils, cells ×10 ⁹ /L	3.73	4.17
Lymphocytes, cells ×10 ⁹ /L	4.21	5.39
Monocytes, cells ×10 ⁹ /L	0.49	0.51
Eosinophils, cells ×10 ⁹ /L	0.34	0.66
Basophils, cells ×10 ⁹ /L	0.09	0.19
Large unstained cells ×10 ⁹ /L	0.51	1.04
Hemoglobin, g/dL	11.7	12.5
Mean corpuscular volume, fL	91	86.36
Mean corpuscular hemoglobin, pg	28.2	26.3
Platelet count, cells ×10 ⁹ /L	336	289
Creatinine, μmol/L	55	44
Glucose, μmol/L	7.63	Not done
Aspartate aminotransferase, U/L	18	33
Alanine aminotransferase, U/L	28.7	70

*bpm, beats per minute; rpm, respirations per minute.

Appendix Table 3. Sequences of primers used to confirm the OPG071:T7171 substitution from monkeypox virus infection in 2 female travelers returning to Vietnam from Dubai, United Arab Emirates, 2022*

Oligo name	Sequences	Length, bp
Mpox-T7171-F	5'-TCATCCGTCCTTCAGACAACA-3'	21
Mpox-T7171-R	5'-CGGCTAAGAGTTGCACATCC-3'	20

*T7171, threonine to isoleucine in amino 717



Appendix Figure. Wearable pulse oximeter device and smartphone display used for remote patient monitoring for monkeypox virus infection in 2 female travelers returning to Vietnam from Dubai, United Arab Emirates, 2022. The wearable device reduces clinical staff contact with patients.