

Pulmonary Infection Associated with *Mycobacterium canariasense* in Suspected Tuberculosis Patient, Iran

Fatemeh Sakhaee, Farzam Vaziri, Golnaz Bahramali, Kambiz Taremiyan, Seyed Davar Siadat, Abolfazl Fateh

Author affiliations: Pasteur Institute of Iran, Tehran, Iran (F. Sakhaee, F. Vaziri, G. Bahramali, S.D. Siadat, A. Fateh); Mohammad Medical Imaging Center, Varamin, Iran (K. Taremiyan)

DOI: <https://doi.org/10.3201/eid2510.190156>

Mycobacterium canariasense had only been isolated in humans from blood and contaminated catheters. We report a case of pulmonary disease associated with *M. canariasense* infection that was identified by multilocus sequence analysis; the illness was initially ascribed to *M. tuberculosis*. *M. canariasense* should be considered a cause of respiratory infection.

Mycobacterium tuberculosis is a widely known cause of pulmonary disease, specifically tuberculosis (TB). However, its symptoms may be similar to those of pulmonary infections caused by other pathogens. We document a case in which disease initially ascribed to *M. tuberculosis* was ruled out through testing and a different mycobacterium, *M. canariasense*, was identified as the likely cause.

The patient was a 67-year-old woman with pulmonary infection living in a village in Afghanistan who traveled to Iran for treatment. Her signs and symptoms included fever, cough, sputum, weight loss, chest pain, and night sweats; the fever and cough had persisted for 6 months. Forty-six years earlier, at 21 years of age, she had experienced a pulmonary TB episode, which was treated with anti-TB drugs. She had no history of smoking or taking immunosuppressive drugs. No other pulmonary diseases were reported.

Results of clinical parameters were normal, apart from an elevated C-reactive protein (CRP) rate (72.4 mg/L) and erythrocyte sedimentation (ESR) rate (85 mm/h). The induration from a tuberculin skin test was 21 mm. A computed tomography scan indicated calcified mediastinal lymph nodes, nodular opacities, and fibrotic changes in the left lower lobe (Appendix Figure, <https://wwwnc.cdc.gov/EID/article/25/10/19-0156-App1.pdf>). The physician assumed a TB reactivation, and chemotherapy was initiated with isoniazid, rifampin, ethambutol, and pyrazinamide. However, the pulmonary symptoms did not disappear after 4 months.

Five sputum samples from the patient were sent to the Pasteur Institute of Iran (Tehran, Iran) in August 2017 for *M. tuberculosis* testing. Results of smear tests indicated partially acid-fast bacilli, whereas all of the samples showed negative results when evaluated by insertion sequence 6110 PCR assay for *M. tuberculosis*. A culture of sputum samples on Lowenstein-Jensen medium after 3 days showed rapidly growing mycobacteria with smooth, small, shiny, and nonpigmented colonies, which turned pale yellow and shinier after 4 days. Phenotypic tests of the isolate were positive on MacConkey agar without crystal violet, urease, Tween 80 hydrolysis, heat-resistant catalase, and arylsulfatase tests. On the other hand, nitrate reductase, growth in 5% NaCl, tellurite, and niacin accumulation tests were negative.

Multilocus sequence analysis was performed for partial *hsp65* and *rpoB* genes and full *16S rRNA* gene, as described in the literature (1–3), and results indicated 100% homology to *M. canariasense* (Figure). This organism was described by Jiménez et al. in a suspected nosocomial outbreak infecting 17 patients during January 2000–September 2002 at a tertiary care hospital in the Canary Islands in Spain (4,5). The phenotypic and genotypic characteristics of the isolate agreed with those for *M. canariasense*, on the basis of guidelines of the American Thoracic Society and the Infectious Disease Society of America (6).

The results of susceptibility testing, performed according to Clinical and Laboratory Standards Institute guidelines (7), indicated that the *M. canariasense* isolate was highly resistant to isoniazid, rifampin, ethambutol, and streptomycin; extremely susceptible to amikacin, levofloxacin, clarithromycin, ceftiofloxacin, ciprofloxacin, imipenem, doxycycline, minocycline, and trimethoprim/sulfamethoxazole; and intermediately susceptible to vancomycin. On the basis of these results, the patient was treated with levofloxacin and amikacin for 17 days. After treatment, sputum samples were collected from the patient over 5 days. The results of smear and culture tests were negative for partially acid-fast bacilli, and the results of a computed tomography scan and CRP and ESR measurements were normal.

Previously, *M. canariasense* had only been detected in the blood of patients and in contaminated catheters (8,9); no study had reported pulmonary infections associated with this isolate. Our results reveal that clinical and radiographic findings of *M. canariasense* pulmonary infection are similar in appearance to those of TB and other nontuberculous mycobacteria infections. However, these findings and improved radiological findings and ESR and CRP levels due to chemotherapy, indicating that *M. canariasense* had been eliminated, strongly suggest that the bacterium could have been the cause of pulmonary disease in this patient.

Although no specific treatment has been recommended for *M. canariasense* infection, combination therapy with




Figure. Neighbor-joining tree of the *hsp65* (A), 16S *rRNA* (B), and *rpoB* (C) genes of an isolate from a patient infected with *Mycobacterium canariensis*, Tehran, Iran (black dots), and other rapidly growing mycobacteria. Outgroup for *hsp65/rpoB* genes was *Mycobacterium tuberculosis* and for the 16S *rRNA* gene was *Tsukamurella paurometabola*. Bootstrap values are represented on branch nodes. GenBank accession numbers are given in parentheses for reference sequences. The nucleotide sequences identified in this study were submitted to GenBank under the following accession numbers: *hsp65*, MK087992; *rpoB*, MK087993; and 16S *rRNA*, MK076944. Scale bars indicate nucleotide substitutions per site.

levofloxacin and amikacin produced a successful outcome in this case; no recurrent pulmonary disease was reported in the patient. However, treatment with other drugs to which *M. canariensis* is susceptible might also succeed. In a 2006 report, Campos-Herrero et al. noted the favorable outcomes produced by fluoroquinolones and amikacin (8). However, the optimal antimycobacterial regimen for *M. canariensis* infection needs to be clearly established in more cases.

Acknowledgments

We thank all the personnel of the Department of Mycobacteriology and Pulmonary Research, Pasteur Institute of Iran, for their assistance in this project. Funding: This study was funded by a grant from the Pasteur Institute of Iran (no. 866).

About the Author

Miss Sakhaee is an expert clinical microbiologist at the Pasteur Institute of Iran. Her primary research interests focus on epidemiologic and clinical aspects of mycobacterial infections.

References

1. Telenti A, Marchesi F, Balz M, Bally F, Böttger EC, Bodmer T. Rapid identification of mycobacteria to the species level by polymerase chain reaction and restriction enzyme analysis. *J Clin Microbiol.* 1993;31:175–8.
2. Turenne CY, Tschetter L, Wolfe J, Kabani A. Necessity of quality-controlled 16S rRNA gene sequence databases: identifying nontuberculous *Mycobacterium* species. *J Clin Microbiol.* 2001;39:3637–48. <https://doi.org/10.1128/JCM.39.10.3638-3648.2001>
3. Adékambi T, Colson P, Drancourt M. rpoB-based identification of nonpigmented and late-pigmenting rapidly growing mycobacteria. *J Clin Microbiol.* 2003;41:5699–708. <https://doi.org/10.1128/JCM.41.12.5699-5708.2003>
4. Jiménez MS, Campos-Herrero MI, García D, Luquin M, Herrera L, García MJ. *Mycobacterium canariensis* sp. nov. *Int J Syst Evol Microbiol.* 2004;54:1729–34. <https://doi.org/10.1099/ijs.0.02999-0>
5. Tortoli E. The new mycobacteria: an update. *FEMS Immunol Med Microbiol.* 2006;48:159–78. <https://doi.org/10.1111/j.1574-695X.2006.00123.x>
6. Griffith DE, Aksamit T, Brown-Elliott BA, Catanzaro A, Daley C, Gordin F, et al.; ATS Mycobacterial Diseases Subcommittee; American Thoracic Society; Infectious Disease Society of America. An official ATS/IDSA statement: diagnosis, treatment, and prevention of nontuberculous mycobacterial diseases. *Am J Respir Crit Care Med.* 2007;175:367–416. <https://doi.org/10.1164/rccm.200604-571ST>
7. Clinical and Laboratory Standards Institute. Susceptibility testing of mycobacteria, nocardiae, and other aerobic actinomycetes—second edition: approved standard (M24-A2). Wayne (PA): The Institute; 2011.
8. Campos-Herrero MI, García D, Figuerola A, Suárez P, Campo C, García MJ. Bacteremia caused by the novel species *Mycobacterium canariensis*. *Eur J Clin Microbiol Infect Dis.* 2006;25:58–60. <https://doi.org/10.1007/s10096-005-0079-6>
9. Paniz-Mondolfi A, Ladutko L, Brown-Elliott BA, Vasireddy R, Vasireddy S, Wallace RJ, Jr, et al. First report of *Mycobacterium canariensis* catheter-related bacteremia in the Americas. *J Clin Microbiol.* 2014;52:2265–9. <https://doi.org/10.1128/JCM.03103-13>

Address for correspondence: Abolfazl Fateh, Pasteur Institute of Iran, Department of Mycobacteriology and Pulmonary Research, No. 69, 12th Farwardin Ave, Tehran, Iran; email: afateh2@gmail.com

Mycobacterium conceptionense Pneumonitis in Patient with HIV/AIDS¹

Sarah M. Michienzi, Rodrigo M. Burgos, Richard M. Novak

Author affiliations: University of Illinois at Chicago College of Pharmacy, Chicago, Illinois, USA (S.M. Michienzi, R.M. Burgos); University of Illinois at Chicago College of Medicine, Chicago (R.M. Novak)

DOI: <https://doi.org/10.3201/eid2510.190444>

Approximately 21 human cases of infection with *Mycobacterium conceptionense* have been reported. However, most cases were outside the United States, and optimal treatment remains uncertain. We report a case of *M. conceptionense* pneumonitis in a patient with HIV/AIDS in the United States. The patient was cured with azithromycin and doxycycline.

Mycobacterium conceptionense is a nonpigmented, rapidly growing, nontuberculous mycobacterium, first isolated in France in 2006 (1). Approximately 21 cases of human infection have been reported (1–10). However, excluding the case we report here, only 2 cases have been reported in the United States (2). Optimal treatment for *M. conceptionense* infection remains uncertain. We report the clinical course and management of *M. conceptionense* pneumonitis in a patient with HIV/AIDS in the United States.

A 47-year-old black cisgender man sought care at an emergency department during 2015 for cough, shortness of

¹Results from this study were presented at the American College of Clinical Pharmacy 2018 Global Conference, October 20–23, 2018, Seattle, Washington, USA.

Pulmonary Infection Associated with *Mycobacterium canariasense* in Suspected Tuberculosis Patient, Iran

Appendix

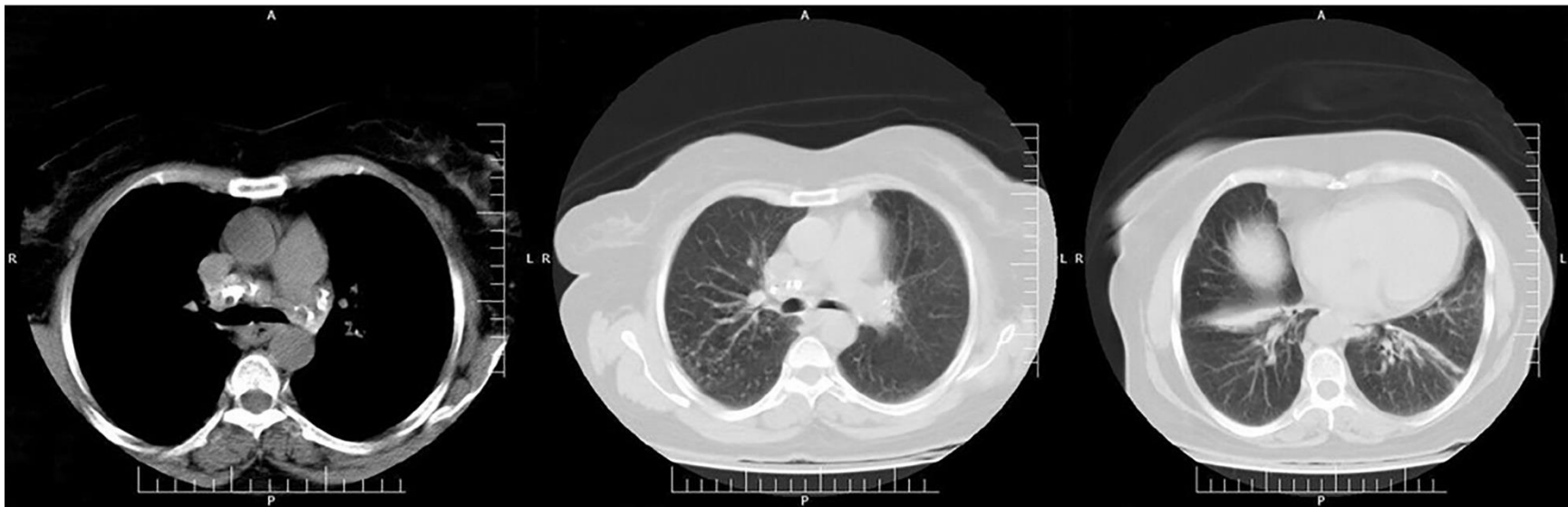

Figure: Chest CT scan image indicating calcified mediastinal lymph nodes, nodular opacities on both sides, a linear band in both lower lobes, partial wedge-shaped collapse in the right lower lobe, and fibrotic changes in the left lower lobe.